CASE REPORT

Congenital CMV Infection with CMV Pneumonitis

Nishant Gopaal*, Jagdish N Sharma, Vijay Agarwal***, Priyanshu Mathur***, Laxman Jadoun******

ABSTRACT

The human cytomegalovirus (CMV) is widely distributed among the human population as one of the most common causes of congenital infections. Congenital CMV infection is seen in approximately 1% of all newborns of which 10% are symptomatic at birth and is a leading cause of sensorineural hearing loss, vision impairment, varying degrees of intellectual disability and delayed psychomotor development.

Here, we present the case of a 7-month-old male child with symptomatic congenital CMV infection presenting with interstitial pneumonitis, bilateral sensorineural hearing loss, chorioretinitis, periventricular leukomalacia, persistent lymphocytosis and failure to thrive. Congenital CMV infection was confirmed by Urine PCR and supported by serology, MRI Brain, BERA, fundus examination and clinical history. Marked improvement in signs and symptoms was observed after treatment with Valganciclovir was initiated according to protocol.

Keywords: Congenital CMV infection, TORCH infections, pneumonitis, microcephaly, sensorineural hearing loss, chorioretinitis, periventricular leukomalacia, failure to thrive

INTRODUCTION

Congenital CMV infection is seen in approximately 1% of all newborns of which 10% are symptomatic at birth[1]. Of the symptomatic newborns almost 70-80% develop late complications that may include sensorineural hearing loss, vision impairment, dental abnormalities, varying degrees of intellectual disability and delayed psychomotor development[2,3]. Congenital CMV infection has emerged as the leading non genetic cause of sensorineural hearing loss[4]. Congenital CMV infection may present with several nonspecific manifestations, although pneumonitis is considered a rare manifestation.

CASE REPORT

A 7-month-old male child was admitted with complaints of fever and respiratory distress for one month. The mother had a history of mild grade fever during the 1st trimester for which no treatment was sought. All antenatal ultrasounds were normal. The child was born full term, normal vaginally delivered, to a primigravida mother and was small for gestational age with birth weight of 2.15 kg. The child was admitted at live day two for neonatal jaundice. Patient had a history of recurrent hospital admissions with complaints of fever and failure to gain weight.

The patient had microcephaly (head circumference<-3SD), weight<-3SD, mild hepato-splenomegaly and bilateral fine crepitations were noted in all lung fields. CNS and cardiovascular systems were found to be normal. Gross motor and verbal milestones were delayed

X-ray revealed ground glass opacities and patchy areas of consolidation involving all lobes of bilateral lungs (Figure 1). USG abdomen showed mild hepato-splenomegaly. Patient had high total leucocyte count (29,000/mm^3) with lymphocytic predominance (60%) and toxic granules in peripheral blood film. SGOT/SGPT was mildly elevated (114U/L, 98U/L), serum bilirubin was normal.

HRCT chest showed multiple nodular areas of patchy consolidation, ground glass haziness and smooth interstitial septal thickening diffusely scattered in bilateral lung fields suggestive of interstitial viral pneumonitis (Figure 2,3). The patient tested negative for COVID-19 and an alternative cause for pneumonitis was sought.

*Junior Resident, *Senior Professor, ***Associate Professor, ****Senior Specialist
Department of Pediatrics, SMS Medical College, Jaipur, India
Corresponding Author:
Dr. Nishant Gopaal
Junior Resident, Department of Pediatrics,SMS Medical College, Jaipur, Rajasthan, India.
Phone: (+91) 7754920632
Email: nishant.gopal@gmail.com

A history of failure to thrive, developmental delay, microcephaly, hepatosplenomegaly, persistently elevated TLC and recurrent viral pneumonitis prompted a search for congenital TORCH infections, and a TORCH profile for mother and child was ordered. The child tested positive for CMV with high serum IgG (101 U/ml) and IgM (54 U/ml) titres. Urine RT-PCR for CMV which was done for confirmation also came positive. The mother tested positive for CMV IgG antibodies. Clinical presentation along with investigations proved the diagnosis of Congenital CMV infection.

A search for other known manifestations of congenital CMV was done. A 3-T MRI Brain showed mild diffuse cerebral atrophy in bilateral frontal lobes with bilateral periventricular leukomalacia and ex-vacuo dilatation of lateral ventricles (Figure 5). BERA revealed bilateral moderate-severe sensorineural hearing loss with fluctuation in the latency of wave V. Direct ophthalmoscopy showed a prominent macular scar with multiple chorioretinal scars in the periphery suggestive of chorioretinitis. 2-D Echo was found to be normal.

Oxygen inhalation by high-flow nasal cannula was given for 15 days due to tachypnea and low oxygen saturation. Treatment was initiated with ganciclovir at 6 mg/kg per dose administered intravenously every 12 hours. This regimen was continued for 4 weeks with serial monitoring of CBC, LFT, RFT for detecting toxicity. There was marked improvement in signs and symptoms. Fever and respiratory distress gradually resolved and the pneumonitis like picture in chest X-ray gradually improved (Figure 4). Patient was the shifted to oral valganciclovir (16 mg/kg/dose bd) after 4 weeks when the patient was clinically stable and able to take oral medications and therapy was planned for the next 6 months.

DISCUSSION

Congenital cytomegalovirus (CMV) infection occurs worldwide, with a prevalence of 0.6 percent in developed countries[5]. The risk of vertical transmission, symptomatic disease and long-term sequelae to the foetus is far higher with primary maternal infection (32%) than with recurrent infection (1.4%)[5,6].

Infants with congenital CMV infection are categorized into symptomatic and asymptomatic based on the clinical findings. Infants with virologically-confirmed congenital CMV and at least one end-organ symptom are classified as symptomatic. Approximately 10% of neonates with congenital CMV infection have symptoms at birth. The common clinical presentations at birth include petechiae (50%-75%), jaundice at birth (40%-70%), hepatosplenomegaly (40%-60%), SGA (40%), microcephaly (35%), sensorineural hearing loss (35%) (SNHL)[7,9]. Congenital CMV infection presenting as pneumonitis is considered a rare manifestation[7,8]. Transaminase and bilirubin levels typically peak within the first 2 weeks of life and can remain elevated for several weeks while thrombocytopenia subsides by one month of age[7]. Less commonly haemolytic anaemia, lymphocytosis and neutropenia has also been observed. Around 10 percent of newborns with symptomatic congenital CMV infection end up with a fulminant course due to viral-associated hemophagocytic syndrome or severe end-organ disease of the CNS, liver, lungs or bone marrow[10].

CMV pneumonitis is estimated to occur in less than 1% of infants with congenital CMV infection with a more fulminant course in case of immunocompromised infants[8]. Congenital CMV pneumonitis may persist for several months if left untreated and can result in development of bronchopulmonary dysplasia due to associated factors such as secondary bacterial pneumonitis, requirement of oxygen inhalation or mechanical ventilator support[8].

Late presentations in infants include hearing loss, vision impairment, intellectual disability and delayed psychomotor development. Ophthalmologic examination reveals chorioretinitis and/or optic atrophy in approximately 10% of symptomatic infants[7]. Neuroimaging findings commonly include periventricular calcifications, lenticulostriate vasculopathy, white matter disease, ventriculomegaly, migrational abnormalities, or periventricular leukomalacia[11]. SNHL is detected in 30-40% of infants with symptomatic disease and 10% of asymptomatic cases[2]. The hearing loss associated with symptomatic congenital CMV is often progressive and profound[6].

A high degree of suspicion must be observed for neonates presenting with petechiae, SGA, thrombocytopenia, hepatosplenomegaly, unexplained jaundice or direct hyperbilirubinemia at birth, sensorineural hearing loss, chorioretinitis or typical features on MRI Brain, and such patients must be subjected to TORCH profile and must be tested for CMV.

Antenatal testing can be carried out by viral culture or CMV DNA detection in amniotic fluid by PCR. Post-natal detection can be performed by running PCR on

either urine, saliva or blood of the neonate. Measurement of CMV genome load may be useful for diagnosis as well as treatment response to ganciclovir therapy. Urine sample is preferred since specificity is low for saliva samples and not all patients are viremic[12]. Serologic testing for CMV IgM/IgG antibody is not preferred as the sole diagnostic test, because of low sensitivity and specificity. Establishing a diagnosis of congenital CMV infection beyond the first year of life is generally not feasible because of low viral loads.

Intravenous (IV) ganciclovir and its oral prodrug, valganciclovir, are the first-line antiviral agents of choice for treatment of congenital CMV disease[13]. Antiviral therapy should be initiated for symptomatic patients as soon as the diagnosis is confirmed, preferably within one month of postnatal life[14]. Treatment must also be offered for asymptomatic patients with isolated hearing loss. Therapy with Valganciclovir must be continued for duration of 6 months according to current guidelines[14].

Monthly CBC, LFT, RFT must be done for monitoring of therapy related toxicity. Monitoring of Urine CMV PCR must also be carried out to look for response to therapy.

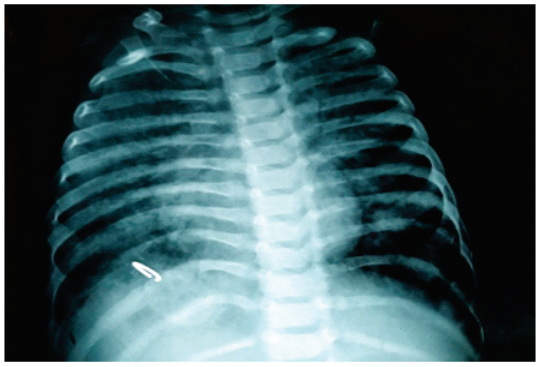

Figure 1: X-Ray Chest with B/L pneumonitis

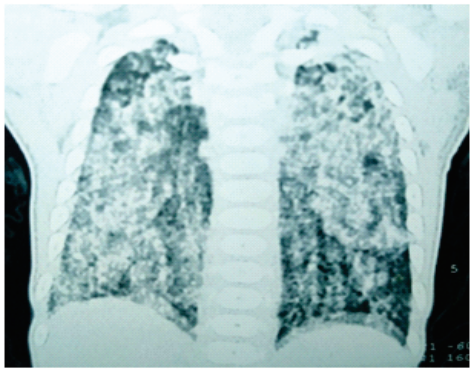

Figure 2: CECT Chest with B/L ground glass appearance s/o Interstitial Pneumonitis

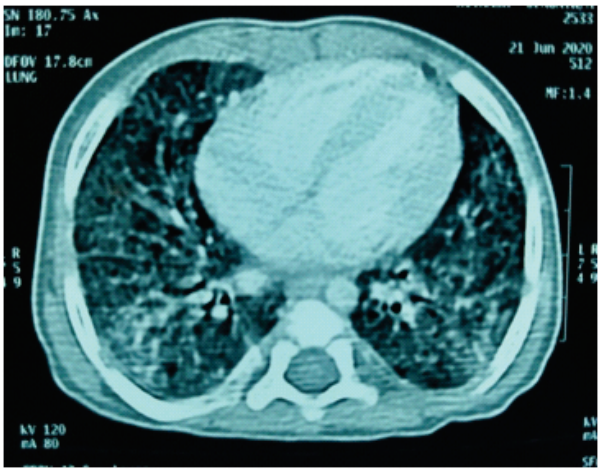

Figure 3: HRCT Chest s/o Interstitial Pneumonitis

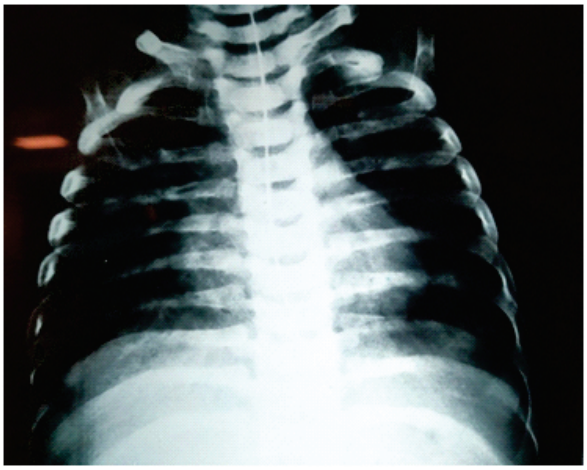

Figure 4: X-Ray Chest -Post therapy with Valganciclovir

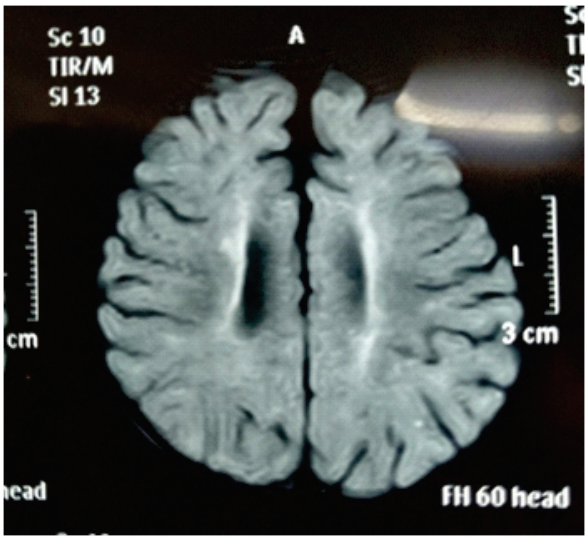

Figure 5: MRI Brain- Periventricular leukomalacia

CONCLUSIONS

Newborns and infants presenting with petechiae, SGA, thrombocytopenia, hepatosplenomegaly, unexplained jaundice or direct hyperbilirubinemia at birth, sensorineural hearing loss, chorioretinitis, unexplained pneumonitis or typical features on MRI Brain should be evaluated for TORCH infections. Congenital CMV infection can rarely present with pneumonitis manifesting as respiratory distress, and early diagnosis and intervention is important to prevent complications like failure to thrive, BPD, chorioretinitis, SNHL and intellectual disability.

REFERENCES

1. Demmler GJ. Infectious Diseases Society of America and Centers for Disease Control. Summary of a workshop on surveillance for congenital cytomegalovirus disease. Rev Infect Dis 1991;13:315–29.
2. Harrison GJ. Cytomegalovirus. In: Feigin and Cherry's Textbook of Pediatric Infectious Diseases, 7th ed, Cherry JD, Harrison GJ, Kaplan SL, et al (Eds), Elsevier Saunders, Philadelphia 2014. p.1969.
3. Hanshaw JB, Scheiner AP, Moxley AW, et al. School failure and deafness after "silent" congenital cytomegalovirus infection. N Engl J Med 1976; 295:468.
4. Morton CC, Nance WE. Newborn hearing screening—a silent revolution. N Engl J Med 2006;354:2151–64.
5. Kenneson A, Cannon MJ. Review and meta-analysis of the epidemiology of congenital cytomegalovirus (CMV) infection. Rev Med Virol. 2007;17:253.
6. Goderis J, De Leenheer E, Smets K, et al. Hearing loss and congenital CMV infection: a systematic review. Pediatrics 2014;134:972.
7. Boppana SB, Pass RF, Britt WJ, Stagno S, Alford CA (1992) Symptomatic congenital cytomegalovirus infection: neonatal morbidity and mortality. Pediatr Infect Dis J 11(2):93–9
8. Coclite E, Di Natale C, Nigro G. Congenital and perinatal cytomegalovirus lung infection. J MaternFetal Neonatal Med. 2013;26:1671-5.
9. Ivarsson SA, Jonssson K, Jonsson B. Birth characteristics and growth pattern in children with congenital cytomegalovirus infection. J Ped Endocrin. 2003;16(9):1233–8
10. Sampath V, Narendran V, Donovan EF, et al. Nonimmune hydrops fetalis and fulminant fatal disease due to congenital cytomegalovirus infection in a premature infant. J Perinatol 2005; 25:608.
11. Giannattasio A, Bruzzese D, Di Costanzo P, et al. Neuroimaging Profiles and Neurodevelopmental Outcome in Infants With Congenital Cytomegalovirus Infection. Pediatr Infect Dis J. 2018;37:1028.
12. Exler S, Daiminger A, Grothe M, et al. Primary cytomegalovirus (CMV) infection in pregnancy: Diagnostic value of CMV PCR in saliva compared to urine at birth. J Clin Virol. 2019;117:33.
13. Kimberlin DW, Lin CY, Sánchez PJ, et al. Effect of ganciclovir therapy on hearing in symptomatic congenital cytomegalovirus disease involving the central nervous system: a randomized, controlled trial. J Pediatr 2003; 143:16.
14. Luck SE, Wieringa JW, Blázquez-Gamero D, et al. Congenital Cytomegalovirus: A European Expert Consensus Statement on Diagnosis and Management. Pediatr Infect Dis J. 2017; 36:1205.

Acknowledgements- The authors would like to acknowledge the contribution of Dr Shankar Tejwani - Professor, Dept. of Radiodiagnosis & Dr Varun Verma and Dr Rajesh KS from Dept. of Pediatrics SMS Medical College.